

Live augmented reality: a new visualization method for laparoscopic surgery using continuous volumetric computed tomography

Raj Shekhar · Omkar Dandekar · Venkatesh Bhat ·
Mathew Philip · Peng Lei · Carlos Godinez · Erica Sutton ·
Ivan George · Steven Kavic · Reuben Mezrich · Adrian Park

Received: 6 July 2009 / Accepted: 27 December 2009 / Published online: 21 February 2010
© Springer Science+Business Media, LLC 2010

Abstract

Background Current laparoscopic images are rich in surface detail but lack information on deeper structures. This report presents a novel method for highlighting these structures during laparoscopic surgery using continuous multislice computed tomography (CT). This has resulted in a more accurate augmented reality (AR) approach, termed “live AR,” which merges three-dimensional (3D) anatomy from live low-dose intraoperative CT with live images from the laparoscope.

Methods A series of procedures with swine was conducted in a CT room with a fully equipped laparoscopic surgical suite. A 64-slice CT scanner was used to image the surgical field approximately once per second. The procedures began with a contrast-enhanced, diagnostic-quality CT scan (initial CT) of the liver followed by continuous

intraoperative CT and laparoscopic imaging with an optically tracked laparoscope. Intraoperative anatomic changes included user-applied deformations and those from breathing. Through deformable image registration, an intermediate image processing step, the initial CT was warped to align spatially with the low-dose intraoperative CT scans. The registered initial CT then was rendered and merged with laparoscopic images to create live AR.

Results Superior compensation for soft tissue deformations using the described method led to more accurate spatial registration between laparoscopic and rendered CT images with live AR than with conventional AR. Moreover, substitution of low-dose CT with registered initial CT helped with continuous visualization of the vasculature and offered the potential of at least an eightfold reduction in intraoperative X-ray dose.

Conclusions The authors proposed and developed live AR, a new surgical visualization approach that merges rich surface detail from a laparoscope with instantaneous 3D anatomy from continuous CT scanning of the surgical field. Through innovative use of deformable image registration, they also demonstrated the feasibility of continuous visualization of the vasculature and considerable X-ray dose reduction. This study provides motivation for further investigation and development of live AR.

Electronic supplementary material The online version of this article (doi:10.1007/s00464-010-0890-8) contains supplementary material, which is available to authorized users.

R. Shekhar (✉) · O. Dandekar · V. Bhat · M. Philip · P. Lei ·
R. Mezrich
Department of Diagnostic Radiology and Nuclear Medicine,
University of Maryland School of Medicine, 22 South Greene
Street, Baltimore, MD 21201, USA
e-mail: rshekhar@umm.edu

R. Shekhar · O. Dandekar · V. Bhat · M. Philip
Department of Electrical and Computer Engineering, University
of Maryland, College Park, MD, USA

R. Shekhar · P. Lei
Fischell Department of Bioengineering, University of Maryland,
College Park, MD, USA

C. Godinez · E. Sutton · I. George · S. Kavic · A. Park
Department of Surgery, University of Maryland School of
Medicine, 22 South Greene Street, Baltimore, MD 21201, USA

Keywords Augmented reality · Continuous CT ·
Image registration · Laparoscopic surgery ·
Surgical visualization · X-ray dose reduction

Minimally invasive laparoscopic surgeries present an attractive alternative to conventional open surgeries, with findings showing that the laparoscopic approach leads to improved outcomes, less scarring, and significantly faster

patient recovery [1, 2]. For certain surgical procedures, such as cholecystectomy, the laparoscopic approach has become the standard of care [3].

Despite the success and increasing applications of laparoscopic surgery for the treatment of various pathologic conditions, visualization of the surgical field is in some ways more challenging with laparoscopic surgeries than with open surgeries [4, 5]. Current laparoscopic images are rich in surface detail but provide no information on deeper features. A surgeon is thus unable to see inside or around exposed surfaces, which potentially affects the precision of current-generation laparoscopic surgeries. Intraoperative appreciation of the visible anatomy together with awareness of underlying structures and vasculature would be valuable for the operating surgeon [5]. The reduced tactile feedback and limited visual displays of minimally invasive surgeries have only heightened the need for improved visualization of target anatomy and visually imperceptible adjacent structures. Laparoscopes are fundamentally limited in providing this information.

To perform true three-dimensional (3D) visualization, a volumetric image of the surgical field is essential—the type of data basic to modern computed tomography (CT) and magnetic resonance (MR) imaging but not to laparoscopes. Prior attempts have used CT and MR imaging data sets of the relevant anatomy to introduce 3D visualization to minimally invasive surgeries [6–8], but because CT and MR imaging scanners are generally unavailable in an operating room and during surgery, these studies have used preoperative CT/MR data sets. Detailed 3D renderings from these data sets can be and have been generated. Moreover, steps have been taken to superimpose these renderings on laparoscopic video to create augmented reality (AR), which provides a larger context than the small field of view in laparoscopy and helps the surgeon to visualize the underlying vessels and other structures.

The aforementioned studies have taken care to bring preoperative CT/MR data sets into alignment with the patient and with the laparoscope's frame of reference. However, one problem with these preoperative images is that they are not reflective of the ever-changing surgical field. Guiding surgeries and basing critical surgical decisions on the 3D rendering from an old snapshot of the target anatomy may be inaccurate and unsafe. This problem will persist as long as preoperative CT/MR images continue to be used as proxies for the dynamic surgical field.

The correct approach to solving this problem is to render live, real-time 3D images of the surgical field—an approach we have proposed and for which this study assessed feasibility. We use a 64-slice CT scanner with continuous scanning capability for intraoperative imaging. Intraoperative visualization during laparoscopy is improved through AR that uses 3D renderings of the

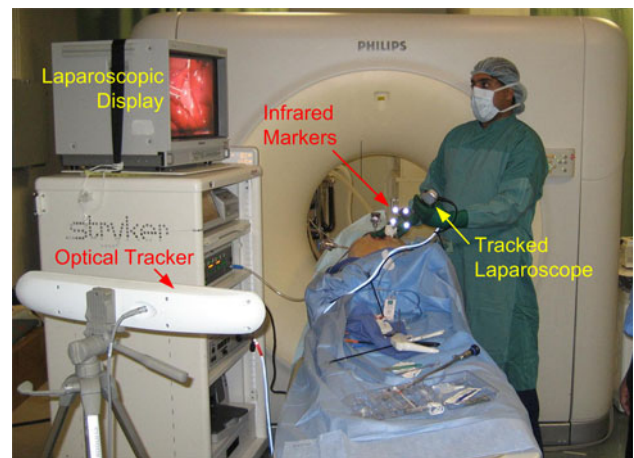


Fig. 1 Typical experimental setup for continuous computed tomography (CT)-based laparoscopic surgery with live augmented reality (AR) visualization. The major equipment includes a CT scanner, a laparoscopic imaging system, and an optical tracker for tracking the laparoscope in CT coordinates

anatomy scanned with live intraoperative CT, a capability we call live AR. Superimposition of such 3D views (acquired instantaneously by CT) on the laparoscopic video after determination of proper alignment has the potential to show hidden structures accurately together with their latest location.

Although computationally and practically more challenging, live AR visualization does not have the limitations of previously reported AR efforts. With the advent of multislice CT scanners, continuous volumetric CT at high frame rates is becoming possible. The continual trend toward more slices (i.e., greater volumetric coverage per rotation) and a higher frame rate (i.e., greater temporal resolution) will make CT increasingly suitable for this surgical imaging task.

We present an offline feasibility testing of live AR made possible with continuous intraoperative CT. One concern with the use of continuous CT is the potential for excessive radiation exposure for patients and surgeons. We therefore also describe a strategy to reduce the radiation dose based on registration of initial and intraoperative CT scans. Our results suggest that the radiation dose can be reduced to clinically acceptable and safe levels, and that with further technical development, live AR can be implemented for routine clinical use. We conclude this article with a discussion of our results, the strengths of our proposed strategy, and future directions for our research.

Materials and methods

A team of surgeons, engineers, radiologists, and support staff collaborated to develop and demonstrate the live AR

visualization concept for laparoscopic surgery in swine. The animal protocol was approved by the institutional animal care and use committee, and the studies were conducted under the supervision of the veterinary staff. Experiments were performed in a CT room with a 64-slice CT scanner (Brilliance 64; Philips Healthcare, Cleveland, OH, USA). A fully equipped laparoscopic surgery suite with necessary instruments and surgical tools was assembled in the CT room before each experiment. Figure 1 shows the typical experimental setup.

Imaging protocol

Figure 2 shows our imaging protocol, including a dose reduction strategy. After the animal was anesthetized, insufflated, and prepared for laparoscopy, we acquired a contrast-enhanced CT scan of the liver at the standard diagnostic dose (X-ray tube voltage, 120 kV; X-ray tube current, 200–250 mA, depending on the animal's weight). Use of the contrast agent ensured that the desired hepatic vessels were highlighted in the CT scan. We adjusted the delay to maximize arterial phase enhancement. We have termed this contrast-enhanced, diagnostic-quality CT scan the “initial CT scan.”

After surgery began, we performed low-dose CT scans of the surgical field continuously and repeatedly. We refer to these subsequent low-dose CT scans as intraoperative CT scans. The intraoperative CT scans were not contrast enhanced because the contrast agents are short acting and cannot be administered repeatedly without causing stress and harm to the kidneys and other organs.

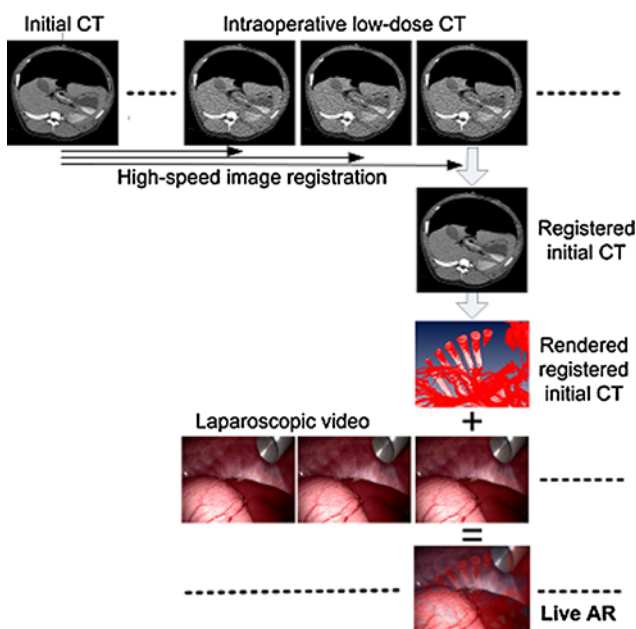


Fig. 2 Flow diagram of our proposed imaging protocol and the built-in dose reduction strategy

The next step in our protocol was rapid registration (i.e., spatial alignment) of the initial and intraoperative CT scans, which allowed us to warp the initial CT scan such that it matched the instantaneous intraoperative anatomy. The registered initial CT scan, which had clinically acceptable image quality and contained the vasculature information, was then substituted for the intraoperative CT scan. This scan was subsequently rendered and superimposed on the corresponding laparoscopic image, accounting for correct camera orientation and optics. By repeating this process for each intraoperative CT scan, the protocol led to accurate and up-to-date AR visualization throughout the surgery—or live AR.

The reduction in dose was the result of using low-dose CT during surgery. We experimented with three different dose or X-ray tube current settings to determine the lowest acceptable dose setting.

Deformable image registration and validation

Registration of the initial and the intraoperative CT scans was performed using a fully automatic and deformable algorithm, which we described in a previous report [9]. For efficiency and eventual clinical implementation, we used a previously reported high-speed implementation of this algorithm [10]. Before image registration, low-dose CT scans were preprocessed using an anisotropic diffusion filter to reduce noise [11]. The initial alignment before image registration was determined by the location data saved with the CT images. The quality of image registration was judged visually by comparing fused initial CT and intraoperative CT scans before and after registration.

To enable objective validation of image registration, we implanted four- to six-point fiducials (2- to 3-mm pieces of a nonmetallic guidewire) randomly into the liver parenchyma under ultrasound guidance and sutured two small calcium markers on the surface of the liver. The average distance between homologous markers before registration was a measure of initial misregistration. After image registration, the same average distance, called target registration error (TRE), determined the accuracy of image registration. Both initial misregistration and TRE were computed.

Procedure for creating and validating AR

Augmented reality is the overlay of the optical image from the laparoscope with a computer-generated image of the CT scan. For accurate spatial registration between the two types of images in AR, the CT scan must be rendered using a virtual camera placed at exactly the same location and in the same orientation as the actual camera to mimic its optics. To achieve this, we used a stationary, tripod-mounted optical

tracker (Polaris Spectra; Northern Digital, Waterloo, Canada) to follow the freehand movement of the laparoscope. The rigid structure of the laparoscope allowed tracking by placement of the manufacturer-provided infrared markers on its length external to the animal's body (Fig. 1).

The optical tracker was controlled by a personal computer (control PC) fitted with a video frame grabber to capture and digitize the laparoscopic video. The control PC ensured temporal synchronization between spatial tracking data from the laparoscope and digitized video frames. The spatial tracking provided the 3D location and orientation of the laparoscope while standard camera calibration steps were followed [12, 13] to determine the camera optics.

We used an open source camera calibration toolbox for this purpose [14]. Cross-linking of the CT coordinate system with the laparoscopic coordinate system allowed us to determine the location and orientation of the virtual camera. A rendering software (Amira; Visage Imaging; San Diego, CA, USA) then was able to use this spatial, temporal, and optical information to generate CT views. The distortion parameters from camera calibration helped to undo the peripheral distortion in the laparoscopic images before they were superimposed on rendered CT images.

The registration of laparoscopic and CT images was achieved through first principles (i.e., matching camera optics with location and orientation). To verify this registration visually, we reused the two aforementioned small calcium markers sutured to the surface of the liver. We took steps to ensure that these markers were both visible by the laparoscope and contained in the CT field of view. The spatial overlapping of these markers in the AR views constituted an independent verification of our method.

Experimental details

We conducted six animal experiments that were incremental in successively developing, testing, and refining our method. The goal was to collect all the data necessary for testing and validating various methodologic steps, for determining the lowest acceptable dose setting, and for creating examples of live AR visualization, all in an offline fashion.

To differentiate live AR from conventional AR and to demonstrate the former's superior accuracy, we created examples of both. After the initial equipment setup and animal preparation, the major steps in our experiments were to calibrate the coordinate systems of the CT scanner and the optical tracker, to implant wire markers in the liver parenchyma, to insufflate, to implant calcium markers on the liver surface, to acquire initial contrast CT, and to acquire intraoperative CT scans.

For live AR, the intraoperative CT imaging included acquiring 100 consecutive volumes (stacks of 64 slices with a 4-cm longitudinal coverage) separated by 1.1 s. The

intraoperative imaging was repeated for three X-ray tube current settings. Continuous laparoscopic imaging from a fixed location accompanied the intraoperative imaging. For creation of conventional AR, intraoperative acquisitions were single (not continuous) snapshots of the anatomy. Immediately after CT, the tracked laparoscope was continuously moved around the anatomy of interest, and the resulting video, lasting approximately 1–3 min, was recorded. These steps were repeated, as before, for three dose settings.

The interval between the initial and intraoperative CTs varied from 10 min to 2 h. After the initial CT, the liver as a whole was manipulated laparoscopically to simulate anatomic shifts from the time of the initial CT. For creation of live AR, we overventilated the animal to cause additional breathing-induced anatomic differences. Live AR, in principle, is capable of following the breathing-induced liver motion observed in both continuous CT and laparoscopic imaging. Because the CT scan used for conventional AR was a snapshot, conventional AR showed misregistration arising from breathing phase differences. The spatial overlapping of the two surface markers helped to compare the two approaches.

For each animal, our experiments allowed creation of three live AR approaches and three conventional AR animations, one for each of the three dose settings. Static frames as well as animated segments were created offline in the laboratory and are presented next.

Results

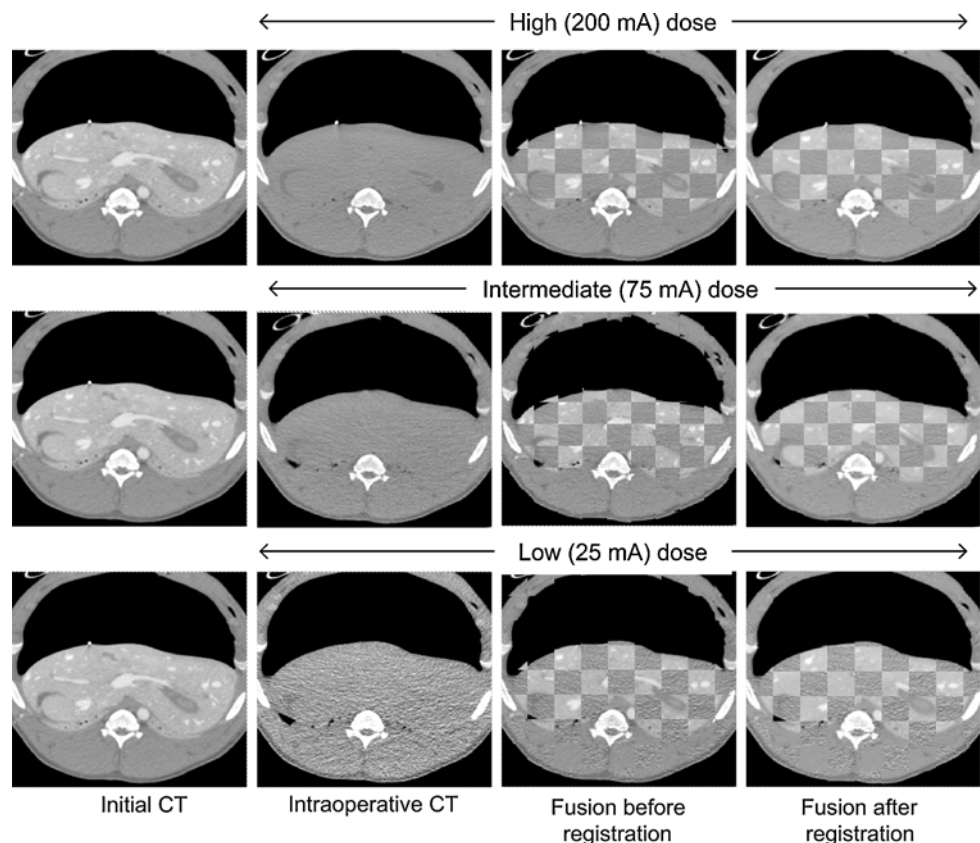
Accuracy of deformable image registration

Deformable image registration plays a crucial role in both reducing the intraoperative radiation dose and enhancing the vessels intraoperatively for creating live AR. Registration must be accurate because any error would affect the accuracy of live AR and consequently the accuracy with which structures can be targeted during surgery.

Figure 3 shows the accuracy of image registration qualitatively. The first column shows an axial slice of the initial diagnostic-quality, contrast-enhanced CT scan. This slice is the same for all the rows, which show the results for deformable image registration of the initial CT with intraoperative CT acquired at three different doses, namely, 200 mA (high dose), 75 mA (intermediate dose), and 25 mA (low dose). The second column shows the axial intraoperative CT slice from the same longitudinal location as that of the initial CT slice in the first column. The third column shows checkerboard fusion of the initial CT and intraoperative CT before registration.

Discontinuities at tile boundaries indicate misalignment caused by liver motion and deformation from user

Fig. 3 Registration of initial computed tomography (CT) with intraoperative CT acquired at three doses: 200 mA (*top row*), 75 mA (*center row*), 25 mA (*bottom row*). The fusion images before and after registration suggest that image registration performed acceptably at all doses



manipulations and breathing. After image registration, however, the misregistration disappears, as shown by the fusion images in the fourth column. A second important finding is that no visually noticeable difference is present in the quality of image registration when the dose is varied from high to low, indicating that the quality of image registration is independent of the intraoperative dose setting for the range explored and that a 25-mA CT can be used intraoperatively as effectively as a higher-dose CT.

The accuracy of image registration was quantitatively examined with the aid of the implanted markers. For each intraoperative dose, image registration reduced the initial misregistration of more than 3 mm to an acceptable level of approximately 1.5 mm (Table 1). Furthermore, the postregistration TRE was relatively independent of the intraoperative dose, indicating again the feasibility of

Table 1 Initial misregistration and target registration error (TRE) after deformable image registration

Intraoperative CT dose (mA)	Initial misregistration (mm)	TRE (mm)
200	3.12	1.47
75	3.63	1.67
25	3.25	1.45

CT Computed tomography

performing intraoperative CT at the lowest dose setting of 25 mA.

The procedures described demonstrate the feasibility of substituting low-dose intraoperative CT with modified initial CT scan. The modified initial CT scan, when rendered, permits 3D visualization of the hepatic vasculature, which is shown next.

Live AR versus conventional AR

We have created examples of both live and conventional AR to draw distinctions between the two and to demonstrate the former's superior accuracy. For conventional AR, we used a single low-dose CT scan of the intraoperative anatomy acquired immediately before a period of AR visualization during which the laparoscope was manipulated and moved around inside the retroperitoneal cavity. The registered initial CT scan replaced the low-dose intraoperative scan. The animal breathed normally during the CT acquisition and the ensuing period of AR visualization.

Figure 4 shows laparoscopic, CT, and AR views of the liver and the surrounding anatomy. The top and bottom rows show the same sequence of views but for two different time instants (i.e., laparoscope positions and orientations). The liver surface in the CT rendering was made

transparent to emphasize the vasculature. Note that the hepatic vessels (as well as the ribs) under the liver surface, invisible in the laparoscopic image, are visible in the CT view. Note also the benefit of image registration for visualization of the vasculature. The vessels are not enhanced in actual intraoperative CT. Image registration allows use of the initial CT for 3D visualization of the intraoperative anatomy while also retaining the vasculature information through contrast enhancement. The AR visualization preserves the surface texture information and optical depth cues from the laparoscope while also exposing the vasculature.

Figure 5 shows two static frames corresponding to two different time points during the period of live AR visualization. The CT is rendered, as before, by making the liver surface transparent. It is important to note that during live AR, two component views remain spatially aligned. Because the CT scanner we used could scan only a 4-cm-

thick section of the abdomen continuously, fewer underlying vessels and ribs were exposed during live AR than during the conventional AR example described earlier. The small field of view notwithstanding, continuous CT scanning allowed the operator to follow the exaggerated breathing motion, making live AR more accurate. An animation of live AR can be viewed on the electronic supplementary material.

Improved accuracy of live AR

Our studies confirmed the expected improved accuracy of live AR compared with conventional AR. Because CT was not repeated during the length of conventional AR, the spatial registration between the laparoscopic and rendered CT views was not perfect. This is evident from the large misregistration of a surface marker seen in the AR view in Fig. 6. The views from the two methods do not overlap

Fig. 4 Laparoscopic (*left column*), computed tomography (CT)-generated (*middle column*), and augmented reality (AR) (*right column*) views for two different time instants during conventional AR. The AR views combine the strengths of the two visualization techniques

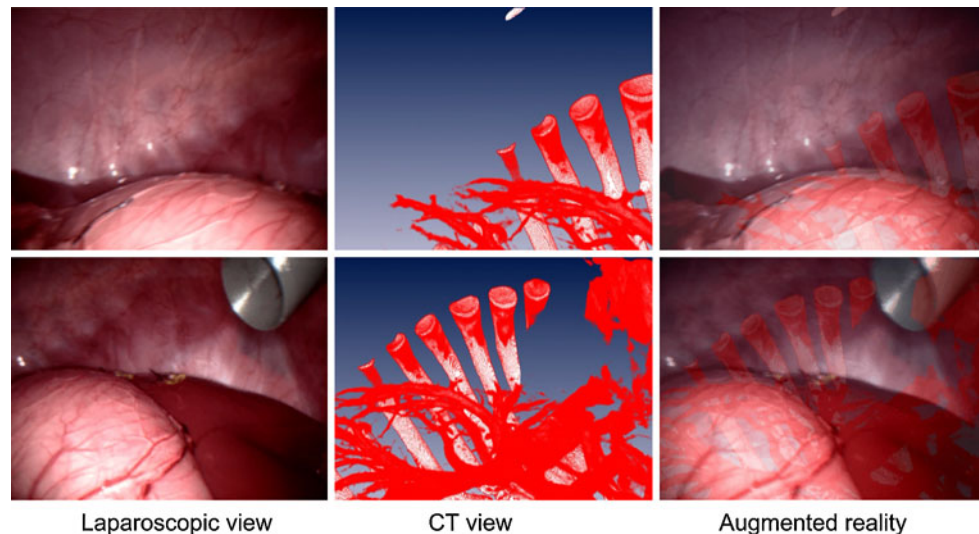


Fig. 5 Laparoscopic (*left column*), computed tomography (CT)-generated (*middle column*), and augmented reality (AR) (*right column*) views for two different time instants during a live AR episode. The CT view is capable of showing the underlying vasculature, the visualization of which is beneficial to laparoscopic surgeons. The AR views combine the strengths of the two visualization techniques

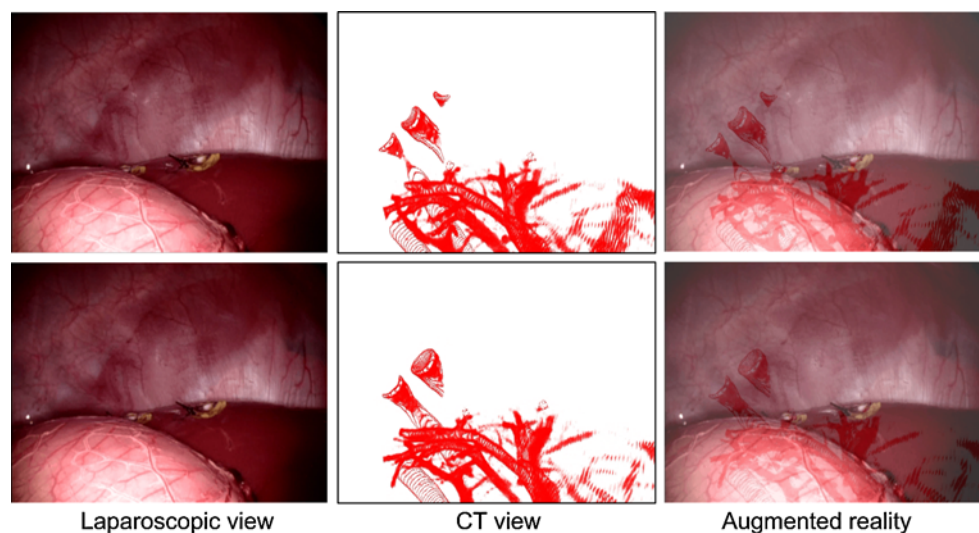
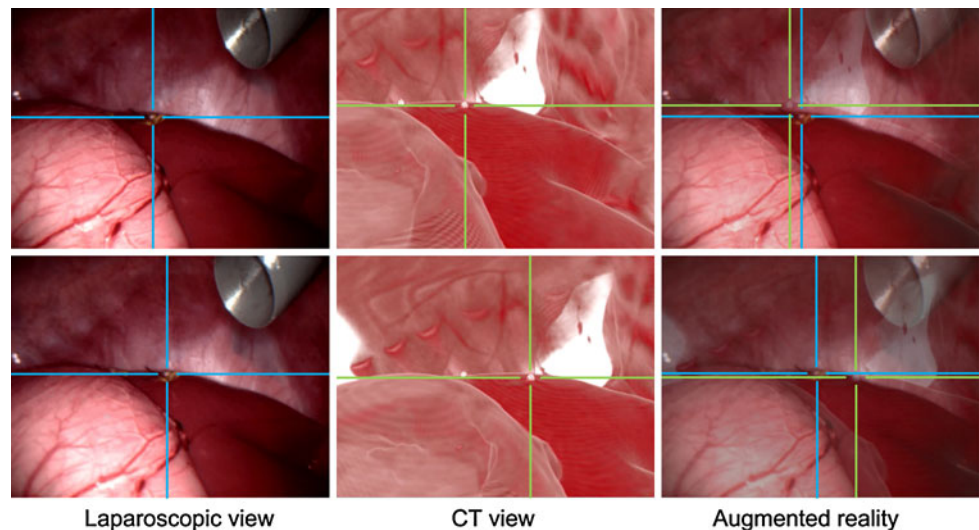


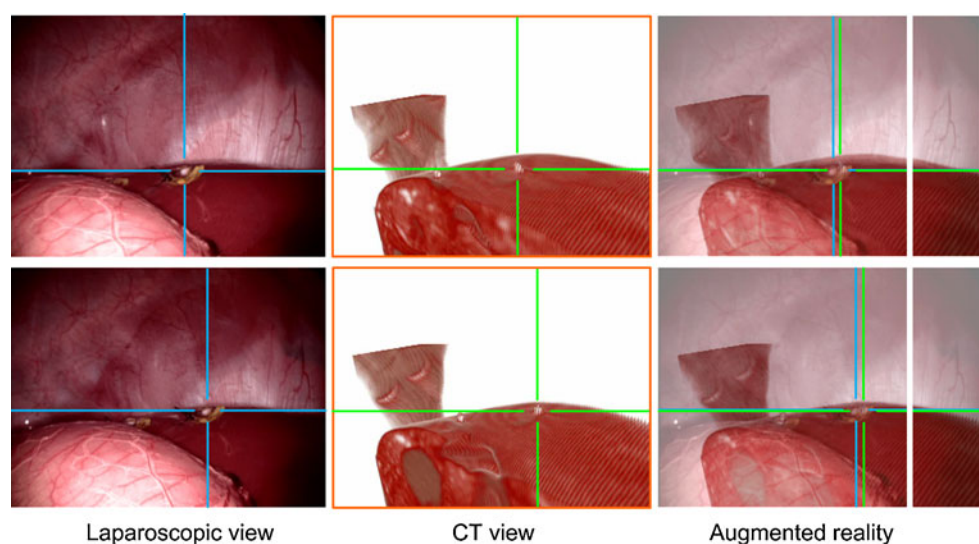
Fig. 6 Conventional augmented reality (AR) views (right column) from two time instants shown in the top and bottom rows. The two crosshairs pointing to a surface marker show a large misregistration caused by breathing that the conventional AR technique is incapable of correcting. A comparison of the results in the top and bottom rows shows that the degree of misregistration is variable and confirms breathing as its source



perfectly. Moreover, the degree of this misregistration varies (compare top and bottom rows) and is dependent on the phase of breathing. It is less pronounced when the breathing phase in which the laparoscopic image was acquired is close to the phase in which the intraoperative CT was acquired. The misregistration is accentuated when the two phases differ. Live AR addresses this misregistration problem inherent in conventional AR because (1) CT is continuously acquired, and (2) the temporal separation between the CT scan is used to create AR and the corresponding laparoscopic frame is minimized.

As before, the initial CT scan was registered with each incoming frame of continuous CT and rendered to visualize the intraoperative anatomy. Marker-based verification (Fig. 7) confirmed the superior registration of component images in live AR. These surface markers were not used to align the two individual views. Instead, they were used merely for verification.

Fig. 7 Live augmented reality (AR) leads to a much improved spatial registration between the laparoscopic and computed tomography (CT) views (right column) from the two time instants shown in the top and bottom rows. A small residual error can be attributed to experimental errors. The superior accuracy of live AR is a result of built-in steps for intraoperative motion compensation, including breathing



Discussion

This study tested the feasibility of an ambitious long-term goal of using new developments in volumetric imaging to enhance intraoperative visualization during minimally invasive surgeries. Despite the introduction of modern high-definition laparoscopes, [15, 16], their 3D visualization capability remains limited. Essentially a video imaging technique, they cannot show structures below the exposed surfaces.

The stereo laparoscope is another recent attempt to enhance 3D visualization of the surgical field [17]. Although depth perception is enhanced with these scopes, hidden structures and vessels still cannot be visualized. Augmented reality, as proposed earlier, provided the missing 3D information but was not accurate because preexisting CT or MR imaging data did not correctly represent the deformable and changing intraoperative

Table 2 Comparison of live augmented reality (AR) and conventional AR

Features	Conventional AR	Live AR
3D imaging	CT or MR imaging performed once, often preoperatively	Initial CT followed by low-dose CT performed continuously during surgery
Vessel enhancement	From contrast enhancement during preoperative imaging	From substitution of intraoperative CT with contrast-enhanced initial CT
Radiation exposure	Not a concern	Concern addressed by low-dose intraoperative CT scanning
Accuracy of AR visualization	Error prone, unable to account for anatomic deformations	Anatomic deformations followed by continuous imaging

CT Computed tomography

anatomy. The most accurate approach is to perform 3D imaging continuously during surgery and use the resulting data for AR. In this study, we demonstrated the feasibility of such a live AR approach. Table 2 compares the distinguishing features of conventional and live AR.

Continuous real-time 3D imaging in the operating room is the first step to equipping operating surgeons with enhanced visualization capabilities. However, continuous 3D imaging has been technologically difficult until recently. Magnetic resonance imaging remains too slow, and significant efforts will be needed to manufacture MR-compatible laparoscopes and surgical instruments. Although real-time 3D ultrasonography currently is available [18, 19], its image quality remains suboptimal compared with that of CT and MR imaging. More important, it cannot image across the pneumoperitoneum.

Multislice CT does is not accompanied by these problems and can image the surgical field several times per second. Newer multislice CT scanners offer high spatial and temporal resolution with high volumetric coverage (up to 320 slices spanning a 12-cm region acquired several times per second) [20, 21]. These reasons, together with tool compatibility and favorable technical development trends, made multislice CT our method of choice for intraoperative imaging.

Two practical challenges with the proposed use of continuous CT are radiation exposure to the patient and surgical team and the need for administering contrast agents to highlight underlying vessels. Deformable image registration, which is integral to our imaging protocol, addresses both these challenges. We also demonstrated the potential of an eightfold reduction in the dose administered to animals in this study by conducting intraoperative CT at 25 mA instead of 200 mA. For a surgeon located 0.5 m from the central CT plane, this amounts to an effective body exposure of 4.6 mR during 10 min of continuous CT operation. Additional dose savings are possible because registration accuracy is retained even at 25 mA, but the CT scanner does not allow further lowering of the current setting.

An earlier study in which dose simulator software allowed us to create lower-dose scans from a standard-dose

CT scan of archived patient images and to explore a larger range of dose settings (as low as 11 mA) indicated acceptable registration at 11 mA, which represented a 20-fold dose reduction [22]. These observations suggest the potential for additional dose reductions.

Visualization of critical underlying structures, especially the vasculature, is important before surgical dissection. Inherent in our imaging protocol and deformable image registration between initial and intraoperative CT data is a scheme to visualize vessels without needing to use a contrast agent continuously. An advantage of 3D rendering of CT data is that the surgeon can interact with this view. For example, the surgeon can virtually rehearse a surgical manipulation and observe the effects in the CT view before actually performing that manipulation. No such interaction is possible with the traditional laparoscopic view.

A promising new approach for visualizing the vasculature was proposed recently by Crane et al. [23], who exploited tissue oxygenation-based differences in three component images obtained using a three-charged couple (CCD) camera. This approach needs further testing, and a potential drawback is that a lack of true volumetric image of the surgical field, in contrast to our method, will not permit the surgeon to “virtually rehearse” a potential manipulation.

Live AR is theoretically the most accurate approach to AR visualization. When compared experimentally, live AR was indeed more accurate than conventional AR (Figs. 6 and 7). A slight misregistration in live AR (Fig. 7; right column) was present due to the slow frame rate of CT, the finite precision of deformable image registration, and the current manual approach to synchronizing CT and laparoscopic imaging systems.

The current study constituted an offline investigation in that it took many days of data processing before live AR visualization could be ready. Slow data processing was not a limitation in proving the concept of live AR, which is a prerequisite to motivating the necessary engineering advances for eventual online implementation. A few other limitations included the use of mostly gross and breathing-induced anatomic changes to simulate intraoperative

changes. More realistic surgical moves could not be tested because they required an operator to perform them while standing next to an operating CT scanner during investigation of continuous low-dose CT. This limitation can be overcome in the future when it is possible to reduce the dose even further.

A lack of integration between the CT scanner and the PC controlling the optical tracker and laparoscopic video frame grabber also was a limitation that necessitated manual temporal synchronization between the intraoperative CT scans and the laparoscopic video. The use of a 0° laparoscope and no camera rotations were limitations that did not interfere with the feasibility testing of live AR and can be overcome rather easily in the future. Additional limitations include the 4-cm coverage and the approximately 1-Hz refresh rate, which will be addressed by newer CT scanners with more slices and faster rotation times.

We believe we succeeded in proving the feasibility of live AR and now must consider the following essential elements in advancing toward routine use of continuous CT-guided laparoscopic surgery and live AR.

1. The CT technology must be improved. The scanner we used, like most current scanners, cannot reconstruct the 64 slices needed during continuous imaging. The scanners also must provide real-time access to the reconstructed images, a capability that does not exist currently. Yet another enhancement would be the ability to lower the X-ray dose to extremely low levels not currently feasible.
2. Image registration must be made even faster. The typical image registration time for 64-slice data currently is approximately 1.5 min, whereas our current experiments required one new registration per second.
3. Much tighter integration is needed among many systems and subsystems (e.g., CT scanner, laparoscope and surgical tools, optical tracker, image registration module, and 3D visualization workstation).
4. Other technical improvements for final implementation will include a redesign of the surgical tools to minimize metal artifacts in CT and more robust calibration devices and procedures. Finally, combining telesurgery with live AR has the potential to prevent the surgical team from receiving any radiation exposure.

In conclusion, our work combines emerging continuous 3D CT imaging with minimally invasive laparoscopic surgery for improved intraoperative visualization in a technique that we have called live AR. Continuous low-dose CT of the dynamic surgical field at safe and acceptable radiation doses and using high-speed deformable image registration to generate diagnostic-quality, contrast-enhanced CT images of the intraoperative anatomy will enable high-quality 3D visualization of the surgical field

during laparoscopy. We have successfully demonstrated the initial feasibility of this concept, which, with further technical enhancements, could be made routine.

Live AR promises to lead to improved precision in laparoscopic surgeries with fewer complications. Because deeply recessed structures can be better visualized, it also is expected that many surgeries currently performed in an open invasive fashion can instead be performed in a minimally invasive manner, expanding the benefits of minimally invasive surgeries to more patients and more procedures.

Acknowledgments This work was supported by U.S. Department of Defense grants DAMD17-03-2-0001 and W81XWH-06-2-0057. We acknowledge the editorial help of Nancy Knight, PhD, and the assistance of Zhitong Yang, PhD, in radiation exposure measurements. Both individuals are affiliated with the Department of Diagnostic Radiology and Nuclear Medicine, University of Maryland School of Medicine, Baltimore, Maryland.

Disclosures Raj Shekhar has an equity interest in IGI Technologies, Inc., a technology startup he has founded. Omkar Dandekar, Carlos Godinez, Erica Sutton, Steven Kavic, Reuben Mezrich, Adrian Park, Venkatesh Bhat, Mathew Philip, Peng Lei, and Ivan George have no conflicts of interest or financial ties to disclose.

References

1. Himel HS (2002) Minimally invasive (laparoscopic) surgery. *Surg Endosc* 16:1647–1652
2. Rosen M, Ponsky J (2001) Minimally invasive surgery. *Endoscopy* 33:358–366
3. Osborne DA, Alexander G, Boe B, Zervos EE (2006) Laparoscopic cholecystectomy: past, present, and future. *Surg Technol Int* 15:81–85
4. Hanly EJ, Talamini MA (2004) Robotic abdominal surgery. *Am J Surg* 188:19S–26S
5. Harrell AG, Heniford BT (2005) Minimally invasive abdominal surgery: lux et veritas past, present, and future. *Am J Surg* 190:239–243
6. Fuchs H, Livingston MA, Raskar R, Colucci D, Keller K, State A, Crawford JR, Rademacher P, Drake SH, Meyer AA (1998) Augmented reality visualization for laparoscopic surgery. In: *Proceedings of the first international conference on medical image computing and computer-assisted intervention*. Lecture Notes in Computer Science, vol 1496. Springer Berlin/Heidelberg Cambridge, pp 934–943
7. Marescaux J, Rubino F, Arenas M, Mutter D, Soler L (2004) Augmented reality-assisted laparoscopic adrenalectomy. *JAMA* 292:2214–2215
8. Mutter D, Bouras G, Marescaux J (2005) Digital technologies and quality improvement in cancer surgery. *Eur J Surg Oncol* 31: 689–694
9. Walimbe V, Shekhar R (2006) Automatic elastic image registration by interpolation of 3D rotations and translations from discrete rigid-body transformations. *Med Image Anal* 10:899–914
10. Dandekar O, Shekhar R (2007) FPGA-accelerated deformable image registration for improved target-delineation during CT-guided interventions. *IEEE Trans Biomed Circuits Syst* 1: 116–127

11. Dandekar O, Castro-Pareja C, Shekhar R (2007) FPGA-based real-time 3D image preprocessing for image-guided medical interventions. *J Real-Time Image Proc* 1:285–301
12. Feuerstein M, Mussack T, Heining SM, Navab N (2008) Intra-operative laparoscope augmentation for port placement and resection planning in minimally invasive liver resection. *IEEE Trans Med Imaging* 27:355–369
13. Shahidi R, Bax MR, Maurer CR Jr, Johnson JA, Wilkinson EP, Wang B, West JB, Citardi MJ, Manwaring KH, Khadem R (2002) Implementation, calibration, and accuracy testing of an image-enhanced endoscopy system. *IEEE Trans Med Imaging* 21: 1524–1535
14. Bouguet J-Y (2009) Camera calibration toolbox for Matlab. Retrieved May 28, 2009, from http://www.vision.caltech.edu/bouguetj/calib_doc/index.html
15. Hagiike M, Phillips EH, Berci G (2007) Performance differences in laparoscopic surgical skills between true high-definition and three-chip CCD video systems. *Surg Endosc* 21:1849–1854
16. Pierre SA, Ferrandino MN, Simmons WN, Fernandez C, Zhong P, Albala DM, Preminger GM (2009) High-definition laparoscopy: objective assessment of performance characteristics and comparison with standard laparoscopy. *J Endourol* 23:523–528
17. Miller A, Allen P, Fowler D (2004) In vivo stereoscopic imaging system with 5 degrees of freedom for minimal access surgery. *Stud Health Technol Inform* 98:234–240
18. Cannon JW, Stoll JA, Salgo IS, Knowles HB, Howe RD, Dupont PE, Marx GR, del Nido PJ (2003) Real-time three-dimensional ultrasound for guiding surgical tasks. *Comput Aided Surg* 8:82–90
19. Sugeng L, Weinert L, Thiele K, Lang RM (2003) Real-time three-dimensional echocardiography using a novel matrix array transducer. *Echocardiography* 20:623–635
20. Kalender WA (2006) X-ray computed tomography. *Phys Med Biol* 51:R29–R43
21. Rogalla P, Kloeters C, Hein PA (2009) CT technology overview: 64-slice and beyond. *Radiol Clin North Am* 47:1–11
22. Dandekar O, Siddiqui J, Walimbe V, Shekhar R (2006) Image registration accuracy with low-dose CT: how low can we go? In: Proceedings of the third IEEE international symposium on biomedical imaging: nano to macro, Institute of Electrical and Electronics Engineers Computer Society, Arlington, pp 502–505
23. Crane NJ, McHone B, Hawksworth J, Pearl JP, Denobile J, Tadaki D, Pinto PA, Levin IW, Elster EA (2008) Enhanced surgical imaging: laparoscopic vessel identification and assessment of tissue oxygenation. *J Am Coll Surg* 206:1159–1166